

## Research Paper

# Morphometric and radiographic studies on radius and ulna of chital (*Axis axis*)

\*Choudhary O.P., Mathur R., Joshi S., Dangi A.

Department of Veterinary Anatomy,  
College of Veterinary and Animal Sciences,  
Rajasthan University of Veterinary and Animal Sciences, Bikaner, (RAJ), INDIA

(Received 06 September, 2012, Accepted 13 October, 2012)

## Abstract

India has been blessed by wide range of biodiversity. There are several wild animals including lion, tiger, elephant, deer, rhinoceros, bear and black panther etc. constitute a huge area of anatomical teaching and research. The present study has been done on the Radius & ulna of chital. The radius was a long bone, relatively shorter and broader as compared to ulna. Radiograph confirmed the presence of medullary cavity in the shaft. Radius was fused to the ulna in the entire length except for two inter-osseous spaces, namely, proximal inter-osseous and distal inter-osseous spaces. The average greatest length of the Radius of Chital was  $18.73 \pm 0.04$  cm. The average maximum Breadth of proximal extremity, shaft and distal extremity was  $4.19 \pm 0.03$  cm,  $2.80 \pm 0.03$  cm and  $3.79 \pm 0.01$  cm, respectively. Ulna was an aborted long bone and was the longest bone of the fore-limb. Radiograph confirmed the presence of medullary cavity only in the proximal part of the shaft. The average greatest length of the ulna of Chital was  $24.30 \pm 0.05$  cm. The average Maximum height of olecranon and maximum breadth of olecranon at anconeal process was  $5.84 \pm 0.02$  cm and  $3.67 \pm 0.02$  cm respectively.

**Keywords:** Chital, Inter-osseous space, Olecranon, Radius, Ulna.

## Introduction

Chital (*Axis axis*) also known as Spotted Deer or Axis Deer, is an antelope which is an endemic species of south Asia, occurring in India, Sri Lanka, Nepal and Bangladesh. Chital have been introduced to the Andaman Islands. The Chital's coat is pinkish fawn, marked with white spots, and its underparts are white. Its antlers, which it sheds annually, are usually three-pronged and curve in a lyre shape and may extend to 75 cm (2.5 ft). Its antler pedicles are proportionally short and its auditory bullae is smaller. It also has large nasals. A well-built stag stands 90 cm at the shoulder and weighs about 85 kg, although males tend to be larger than females. Its lifespan is around 8–14 years.

## Material and Methods

In this study six specimens of adult Chital (*Axis axis*) were used which were studied at Bikaner and Jaipur zoos. Three of the specimens were of male and three of female. The sex was confirmed by the history taken from the persons engaged in burying the dead animals in the zoo premises. The permission for the specimen's collection was sought from Principal Chief Conservator of Forest (PCCF), Rajasthan. The

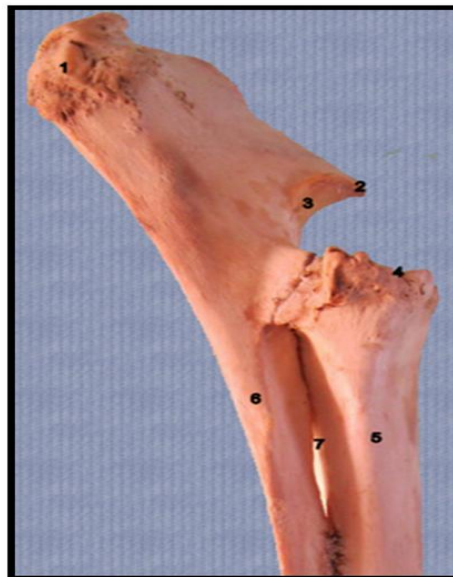skeletons were studied at the Bikaner and Jaipur zoo vide approval letter no. F,3(02) Tech-II/CCF/2010/6393, dated 1.12.2010 and F,3(04) Tech-II/CCF/2010/6937-38, dated 31.05.2011.

The skeletons were dug out from the graveyard located in the premises of the office of Deputy Conservator of Forest (WL), Bikaner and Jaipur. Afterwards, the specimens were put into hot water for maceration in a large aluminum bowl. A net was wrapped around each forelimb for better recovery of small bones. The bones were washed with bleaching powder to remove the offensive smell and were sun-dried afterwards for two to three days. After recovery of all the desired bones, these were kept in separate boxes. The gross, biometrical and radiographic study was carried out in the Department of Veterinary Anatomy and Veterinary surgery and Radiology, College of Veterinary and Animals Science, Bikaner (Rajasthan) under supervision of the zoo personals.

## Results and Discussion

### Radius

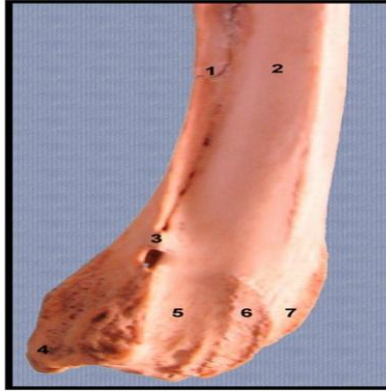
In the present study, radius and ulna were fused through the entire length except for two inter-osseous spaces, namely, proximal and distal inter-osseous spaces similar to the observation of <sup>[11]</sup> in Moschida, most Antelopes, sheep, Elk, Rein-deer, Fallow-deer,<sup>[14]</sup> and <sup>[12]</sup> in ox, <sup>[1]</sup> in ruminants, <sup>[5]</sup> in sheep, <sup>[13]</sup> in Black Bengal goat and <sup>[3]</sup> in Antelope. These findings are inconsistent with the findings of <sup>[5]</sup> and <sup>[4]</sup> in horse where the ulna was fused at the proximal third of the radius and presented only proximal inter-osseous space and <sup>[10]</sup> in dog, where two bones attached to each other only at their ends. (Figure1)



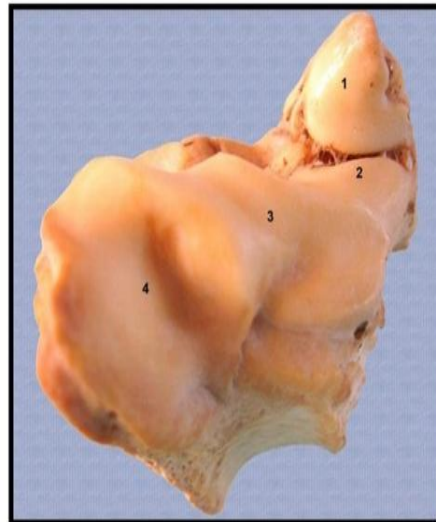**Figure 1: Proximal extremity of right radius and ulna**

1. Olecranon process,
2. Anconeus,
3. Semilunar notch,
4. Proximal extremity of radius,
5. Radius,
6. Ulna,
7. Proximal inter-osseous space

The radius in the present study was a long bone, relatively shorter and broader as compared to ulna similar to the findings of <sup>[11]</sup> in true ruminants, <sup>[14]</sup> and <sup>[12]</sup> in ox. These findings are inconsistent with the observation of <sup>[6]</sup> in cat where radius and ulna were of almost equal thickness. The shaft was compressed cranio-caudally. Its cranial surface was convex, and smooth proximally. Distally it possessed three grooves namely, medial, central and lateral which confirms the findings of <sup>[12]</sup> in ox and <sup>[5]</sup> in horse. The central one was the widest. (Figure 3)



**Figure 2: Lateral view of distal extremity of right radius and ulna**  
 1. Ulna, 2. Radius, 3. Distal inter-osseous space, 4. Styloid process,  
 5, 6, 7. Lateral, middle and medial groove



**Figure 3: Distal extremity of right radius and ulna**  
 1. Styloid process, 2. Facet for ulnar carpal, 3. Facet for intermediate carpal,  
 4. Facet for radial carpal

The Proximal extremity was irregularly oval in outline with its long axis being medio-lateral in direction similar to the reports of <sup>[10]</sup> in dog, on the contrary <sup>[16]</sup> reported that it was triangular in outline in elephant. The nutrient foramen in the present study was found variably between lateral border and lateral margin of proximal inter-osseous space, which is more or less similar to the observations of <sup>[12]</sup> in ox, however, it is located slightly above the middle of the caudal surface of the radius in dog <sup>[10]</sup> Distal extremity was thicker and larger than the proximal one, which is similar to the observations of <sup>[10]</sup> in dog. On the distal end, oblique articular surface was presented, which is similar to the findings of <sup>[2]</sup> in pig, <sup>[14]</sup> and <sup>[12]</sup> in ox. It consisted of three articular areas for first three carpal bones of the proximal row. The medial one was the largest, while the middle one is intermediate in size. The lateral one was the smallest, which is similar to horse. <sup>[5]</sup> On the contrary, the middle one is the largest in dog. <sup>[10]</sup>

The average greatest length of the Radius of Chital was  $18.73 \pm 0.04$  cm, while <sup>[13]</sup> measured that in Black Bengal goat the radius was  $11.12 \pm 0.23$  cm in length. (Table 1)

**Table 1: Different measurements of Radius**

Specimen no.	Description		Greatest Length (Lgr)	Maximum breadth of shaft (Bs)	Maximum breadth of proximal extremity (Bp)	Maximum breadth of distal extremity (Bd)
1.	Adult female-1	Left	18.85	2.92	4.24	3.98
		Right	18.87	2.94	4.22	3.96
2.	Adult female-2	Left	18.64	2.75	4.08	3.89
		Right	18.66	2.77	4.06	3.88
3.	Adult female -3	Left	18.98	2.82	4.36	3.64
		Right	18.99	2.81	4.36	3.63
4.	Adult male -1	Left	18.72	2.99	4.07	3.98
		Right	18.71	2.96	4.08	3.99
5.	Adult male-2	Left	18.49	2.76	4.29	3.51
		Right	18.43	2.74	4.26	3.53
6.	Adult male-3	Left	18.72	2.61	4.15	3.75
		Right	18.74	2.63	4.15	3.74
	<b>Average</b>		<b>18.73</b>	<b>2.80</b>	<b>4.19</b>	<b>3.79</b>
	<b>SD</b>		<b>0.171</b>	<b>0.124</b>	<b>0.11</b>	<b>0.18</b>
	<b>SE</b>		<b>0.049</b>	<b>0.035</b>	<b>0.031</b>	<b>0.015</b>

## ULNA

In this study ulna was an aborted long bone. It was the longest bone of the fore-limb similar to the observations of <sup>[10]</sup> in dog. It consisted of a shaft and two extremities.

The shaft was roughly prismatic in Chital, which is in accordance with the observations of <sup>[14]</sup> and <sup>[12]</sup> in ox, <sup>[10]</sup> in dog and <sup>[5]</sup> in horse. It was strongly curved and presented three surfaces. Cranial surface was convex vertically and transversely, which is similar to the findings of <sup>[10]</sup> in dog. It fused with radius except for two locations of inter-osseous spaces. This surface was arched at proximal inter-osseous space. Nutrient foramen was not recorded in the present study in Chital, while it is located on the cranial surface in dog <sup>[10]</sup> and horse <sup>[5]</sup>.

Proximal extremity comprised of olecranon process and semi-lunar notch. The olecranon process was directed dorso-caudally and had a well-developed summit, the tuber olecrani. It was the most massive process of the ulna similar to the findings of <sup>[11]</sup> in most ruminants and <sup>[14]</sup> and <sup>[12]</sup> in ox. It had two surfaces and two borders. The medial surface was slightly concave and lateral surface was slightly convex. Cranial border was thin, and distally presented a beak like projection, the anconeus process. This process is similarly formed in ox <sup>[12]</sup> and in horse <sup>[5]</sup>.

The distal extremity was projected downwards known as styloid process and fused with the radius for the formation of the lateral facet, in contrast, ulna fused to the shaft of radius without forming styloid process in horses<sup>[5]</sup>. However, distal extremity of radius forms styloid process in dog<sup>[10]</sup> and in dromedary<sup>[15]</sup> (Figure 2 and 3). The average greatest length of the ulna of Chital was  $24.30 \pm 0.05$  cm. However,<sup>[13]</sup> found that in Black Bengal goat, the total length of ulna was  $14.20 \pm 0.20$  cm. (Table 2)

**Table 2: Different measurements of Ulna**

Specimen no.	Description		Greatest Length (Lgu)	Maximum height of olecranon (Ho)	Maximum breadth of olecranon at acromian (Boc)
1.	Adult female-1	Left	24.05	5.97	3.64
		Right	24.04	5.93	3.66
2.	Adult female-2	Left	24.47	5.79	3.79
		Right	24.49	5.78	3.76
3.	Adult female -3	Left	24.18	5.75	3.54
		Right	24.19	5.79	3.51
4.	Adult male -1	Left	24.42	5.88	3.77
		Right	24.41	5.89	3.78
5.	Adult male-2	Left	24.53	5.90	3.68
		Right	24.55	5.89	3.65
6.	Adult male-3	Left	24.17	5.77	3.63
		Right	24.11	5.75	3.69
	<b>Average</b>		<b>24.30</b>	<b>5.84</b>	<b>3.67</b>
	<b>SD</b>		<b>0.194</b>	<b>0.076</b>	<b>0.09</b>
	<b>SE</b>		<b>0.056</b>	<b>0.022</b>	<b>0.025</b>

## Conclusion

It is concluded that the findings of present study was similar to the findings of Ox, Sheep, Goat but disagreements with the findings of Horse, Dog, Camel, Indian gazelle and Elephant.

## References

1. Bradley O.C. Outlines of Veterinary Anatomy, Part-I The Anterior and Posterior Limb. William R. Jenkins, Veterinary Publisher and Bookseller, New York, **83-86 (1896)**.
2. Chauveau A. Second English edition (Translated and edited by George Fleming). The Comparative Anatomy of the Domesticated Animals. New York D. Appleton and Company, **98-119 (1905)**.
3. France D.L. Human and Nonhuman Bone Identification, A Color Atlas, CRC Press, Tyler & Francis Group, 188-331, **(2009)**.

4. Frandson R.D., Wilke, W.L. and Fails, A.D. Anatomy and Physiology of Farm Animals, Willey Blackwell, 71-74, **(2009)**.
5. Getty R. Sisson and Grossman's The Anatomy of the Domestic Animals. W.B. Saunders Comp. Philadelphia. 273-296, **(1975)**.
6. Kalita A. and Bhattacharyya R. Comparative Anatomy on the Appendicular Skeleton of the Domestic Cat and Local Dog of Mizoram, Souvenir and Abstract, Silver Jubilee National Symposium on Advancement in Veterinary Anatomy Teaching & Research with Special Reference to Their Clinical Application and XII Annual Convention of Indian Association of Veterinary Anatomists, 8, **(2008)**.
7. Konig H.E. and Liebich H.G. Veterinary Anatomy of Domestic Animals, 3rd Edition, Schattauer, Stuttgart, Germany, 49-104, 145-164, **(2006)**.
8. Ladukar O.N., Bhamburkar V.R., Dalvi R.S. and Banubakode S.B. Comparative morphometric evaluation of radius and ulna in deer and bear. Tech. Bul. XII Convention and National Symposium of IAVA, 6, **(1998)**.
9. McFadyean Osteology and Arthrology of Domestic Animals, 4th edition, edited by Hughes, H.V. and Dransfield, J.W. London Bailliere, Tindall and Cox., 130-172, **(1953)**.
10. Miller, M.E., Christensen, G.C. and Evans, H.E. Anatomy of the Dog. WB Saunders Company, Philadelphia, USA, 64-78, **(1964)**.
11. Owen R., On the Anatomy of Vertebrates. Part II: Birds and mammals, London Longmans, Green, and Company, 482-484, **(1866)**.
12. Raghavan, D. Anatomy of ox. Indian Council of Agricultural Research, New Delhi, 97-117, **(1964)**.
13. Siddiqui M.S.I., Khan M.Z.I., Sarma M., Islam M.N. and Jahan M. R., Macro-anatomy of the bones of the forelimb of Black Bengal Goat (*Capra hircus*): Bangladesh J. of Vet. Med., 6(1), 59-66, **(2008)**.
14. Sisson S. A Text Book of Veterinary Anatomy. W. B. Saunders Company, Philadelphia and London, 127-131, **(1911)**.
15. Smuts M. and Bezuidenhout A. J. Anatomy of the Dromedary. Clarendon Press, Oxford, UK., 24-34, **(1987)**.
16. Talukdar S. R., Kalita S. N. and Baishya, G. Gross Anatomical Study on the Radius of Adult Indian Elephant (*Elephas maximus*), Souvenir and Abstract, Silver Jubilee National Symposium on Advancement in Veterinary Anatomy Teaching & Research with Special Reference to Their Clinical Application and XII Annual Convention of Indian Association of Veterinary Anatomists, 62 **(2008)**.