

International Journal of Research in Biosciences
Vol. 5 Issue 2, pp. (30-39), April 2016
Available online at <http://www.ijrbs.in>
ISSN 2319-2844

Research Paper

Study of the biological effect of an aqueous extract from a medicinal plant (*Costus spicatus*) F1 mice treated with hyperglycaemic diet

Nascimento C.C.H.C.^{1,3}, Armada-Dias L.C.³, Azevedo L.A.C.^{1,2}, Camacho A.C.L.F.⁴, Oliveira J.F.F.³, Gomes M.L.⁵, Nascimento S.F.^{1,3}, Vasconcelos S.D.D.de^{1,6}, Nogueira R.I.⁷, Barreto A.S.^{1,8}, *Diré G.F.^{1,3}.

¹Laboratory of Chemical and Biological Analysis (LAQB), Foundation State University Center of the West Zone (UEZO), Avenue Manuel Caldeira de Alvarenga, 1203, Campo Grande, Rio de Janeiro, 23070-200, BRAZIL

²Foundation Support Technical School (FAETEC/Rio de Janeiro, BRAZIL)

³Estácio de Sá University (UNESA), Rio de Janeiro, BRAZIL

⁴Department of Nursing and Administration Fundamentals (MFE/UFF), Aurora de Afonso Costa School of Nursing of the Fluminense Federal University (UFF), Niterói, Rio de Janeiro, BRAZIL

⁵National Cancer Institute, Nuclear Medicine (HC1/INCa), Rio de Janeiro, RJ – BRAZIL

⁶Federal Center of Technological Education Celso Suckow da Fonseca - CEFET-NI

⁷Brazilian Agricultural Research Corporation (Embrapa), Rio de Janeiro, BRAZIL

⁸Brazilian Association of University Education Abeu/UNIABEU, Rio de Janeiro, BRAZIL

(Received March 02, 2016, Accepted March 30, 2016)

Abstract

The incidence of chronic diseases is increasing throughout the world. Diabetes is a disease, and approximately 80% of the diabetic population living in developing countries. There is a growing trend towards the use of complementary and alternative medical practices in Diabetes. Diabetes mellitus is a metabolic disorder of glucose metabolism which correlates with postprandial hyperglycemia and oxidative stress. The control of the blood glucose level is essential in managing diabetes. The present study tested the hypothesis that an aqueous extract of *Costus spicatus* a medicinal plant anti hyperglycemic possibly have the ability to promote the decrease of glucose levels in animals treated with diet-induced hyperglycemia. It was observed the average glucose levels in blood of animals that received only hyperglycemic diet for 8 days and were treated with saline (0.9% NaCl) for 16 days and the average blood glucose of hyperglycemic animals that received the diet over 8 days and treated with an aqueous extract of *Costus spicatus* for 16 days. From the statistical analysis of the results of this study, it can be speculated that the decrease in glucose was response to the *Costus spicatus* effect in the treated group ($p < 0.005$) and was associated with a potentiation of insulin release from pancreatic islets and strengthening use peripheral glucose.

Keywords: *Costus spicatus*, aqueous extract, hyperglycaemic, medicinal plant, diabetes.

Introduction

The use of medicinal plants have been used extensively in the treatment and prevention of the disease in the population in recent years. Throughout the world indigenous peoples have used the plants millennia for medicinal purposes, and these skills were passed from generation to generation to spread with the emergence of modern civilizations^[1]. Thus, the global scientific community has been

working to confirm the popular use of medicinal plants, thus contributing to the safe use and discovery of new drugs.

The cane of the swamp (*Costus spicatus* Jacq.) Zingiberaceae family species, also known as cane of the bush or cane monkey, is a native plant in almost all of Brazil, mainly in the Atlantic Forest and the Amazon region^[2]. It is characterized for being a perennial, rhizomatous, unbranched, erect, which can reach 2 m high. The plant is used in folk medicine, particularly in the Amazon region, its popular use is associated with cleansing and diuretic action, relieving urinary tract infections and help in removing kidney stones^[3].

Costus spicatus (Jacq) Swis a herbaceous species with neotropical distribution belonging to the family Costaceae^[4,5,6]. It is a perennial plant whose aerial part can reach 1.0 to 2.0 meters in height, native throughout most of Brazil, mainly in the Atlantic Forest and Amazon region^[7]. The leaves are spirally arranged with invaginating the extension base with terminal inflorescence, bracts spiral dense, intertwined, glabra, and red^[8].

Due to the similarity in morphology and applications, the popular denominations *Costus* genus representatives are: sugar-soft, canarana, monkey cane, poor-old cane of the swamp^[9, 7]. *Costus spiralis* Rosc. and *Costus spicatus* (Jacq.) are known to have the same uses in traditional medicine^[10]. *Costus speciosus* (Koen ex. Retz.) Sm. (crepe ginger, family Costaceae) is an ornamental plant used in traditional medicine for the treatment of inflammation, rheumatism, bronchitis, fever, headache, asthma, flatulence, constipation, helminthiasis, leprosy, skin diseases, hiccough, anemia, as well as burning sensation on urination^[11].

In Brazilian folk medicine, the *C. spicatus* tea is used with depurative purposes, astringent and diuretic^[12, 9]. Boorhem et al. (1999)^[12] describe the decoction of the vegetative plant parts of the species active in the treatment of vaginal irritation, leukorrhea and ulcers. The juice of fresh stem dilute is effective in the treatment of gonorrhoea, syphilis, nephritis, insect bites, bladder problems and diabetes^[13, 9]. The sheets can be combined with *Bonamia ferruginea* "vine-Tuira" (Choisy) Hallier in the form of combinations (potions) in the treatment of malaria, hepatitis and diabetes^[14].

The *Costus spicatus* Jacq. S. W. (Cactaceae / Zingiberaceae), in Brazil, is a medicinal plant found in coastal rainforests. The rhizome of this plant is used for the treatment of complaints of the bladder and urethra and to expel kidney stones. The infusion of the aerial parts is used to treat colds, sore throat, dysentery and diarrhea^[15]. Their use in traditional medicine includes the use of leaves, stems and rhizomes as a diuretic and tonic^[7].

The antioxidant action of species *Costus* is not yet well understood. However, studies show that many species of Zinziberaceae can sequester free radicals^[16].

The oxygen species (ROS) are molecules with an unpaired electron in the final orbital making them highly unstable, extremely reactive, and enormous capacity to combine with various members molecules of the cellular structure, such as DNA, proteins, carbohydrates and lipids^[10]. The ability to combine the cellular structures is associated with multiple pathological processes such as cancer, atherosclerosis, and Alzheimer's disease, and other disorders, and normal aging process^[17].

Chemical studies of the aerial parts of *Costus spicatus* allowed the isolation of new flavonoid diglycosides such as tamarixetin 3-O-neohesperidoside the Kaempferol 3-O-neohesperidosidesix flavonoids and other compounds such as 3-O-neohesperidosídeo quercetin^[15]. In its chemical composition is also recorded the presence of oxalic acid, tannins, saponins, mucilages and pectin^[18].

Hegde et al., (2014)^[19] reported that *Costus igneus* Nak and *Costus pictus* D. Don, commonly known as spiral flag, is a member of Costaceae and a newly introduced plant in India from South and Central America. It is a perennial, upright, spreading plant reaching about two feet tall, with spirally arranged leaves and attractive flowers. In southern India, it usually grows as an ornamental plant and its leaves are used as a dietary supplement in the treatment of diabetes mellitus. Recently, a number of researches have been carried out to evaluate the anti-diabetic potential of this plant. Besides, it has been proven to possess various pharmacological activities like hypolipidemic, diuretic, antioxidant, anti-microbial, anti-cancerous. Further, various phytochemical investigations reveal the presence of

carbohydrates, triterpenoids, proteins, alkaloids, tannins, saponins, flavonoids, steroid, and appreciable amounts of trace elements.

Many plants extracts containing phenolic compounds, mainly flavonoids and tannins, appear to have significant antioxidant activity, able to reduce the harmful effects caused by free radicals^[10]. However, it has also been shown to reports suggesting that a diet rich in phenolic compounds display prooxidant and cytotoxic properties under certain conditions^[20].

Azevedo et al (2014)^[21] found that the *Costus spicatus* displays all classes of metabolites described above, some of which have biological activity already known, making it necessary to carry out quantitative studies and research demonstrating their pharmacological effects, which contribute to the development of new drugs.

Diabetes mellitus includes a group of metabolic diseases characterized by hyperglycemia resulting from defects in insulin secretion and/ or its action^[22]. Hyperglycemia is manifested by symptoms such as polyuria, polydipsia, weight loss, polyphagia and blurred vision or acute complications that can lead to life-threatening: diabetic ketoacidosis and hyperosmolar hyperglycemic non ketotic syndrome. Chronic hyperglycemia is associated with damage, dysfunction and failure of various organs, especially the eyes, kidneys, nerves, heart and blood vessels. Intervention studies have shown that obtaining the best possible glycemic control delayed the onset of microvascular chronic complications, although it has not had a significant effect in reducing mortality from cardiovascular disease^[23].

The practice of using household ingredients as complementary medicine is common. Some herbal medicines and their methods of preparation have evidence of limited effectiveness. Given the frequent use by diabetics each of these needs to be documented for reference and scientifically explored on the hypoglycemic potential^[24].

The objective of this study is to assess the possible hypoglycemic effect of an aqueous extract of *Costus spicatus* in *F1* mice subjected to a hyperglycemic diet.

Materials and Methods

Sample Plant and Collection

We used the leaves of *Costus spicatus* collected during flowering (December-January) on the Site My Dream, the municipality of Itacuruça, RJ, Brazil. The choice of the time of collection was based on data from the literature indicate that concentrations of flavonoid substances tend to increase during this time. This is due to the action of flavonoids as attractors of pollinators and as co-pigments of anthocyanidins^[25]. A voucher specimen of the species will be deposited in the Herbarium of the UFRJ National Museum for botanical certification by an expert.

Preparation of extract

Costus spicatus leaves were dried in an oven with circulating air at 40 °C, manually crushed and stored in amber glass jar. The crude aqueous extract was obtained by infusion of bark powder using distilled water as liquid extractor. The extract was lyophilized and stored in amber glass bottle under refrigeration at a minimum temperature of - 20 °C.

Characterization of the Sample

Organoleptic characterization: Characteristics were observed related to the color, odor, flavor and texture and pH of the aqueous extracts of leaves of *Costus spicatus*^[26].

Experimental animals

The use of animals in the experimental model described on this scientific paper, was authorized, upon the approval of the research project in which consists the methodology developed in this scientific work by the Committee of Ethics in the use of animals (CEUA) of the Foundation State University Center of the West Zone (UEZO), headquartered in the city of Rio de Janeiro in Brazil. The animals used in this study were *F1* male rats about two months old, kept under care related to food (chow and water ad libitum) except during the experimental phase, temperature (22 ± 25 ° C) and cycles of 12 hours light/ dark in the Vivarium of the West Zone State University Center (UEZO).

Hypoglycemic effect assessment Extract

Induction of hyperglycemia Fasting in F1 Mice

In this study F1 male mice were used (n = 10), aged 8 weeks. The animals were divided into two groups: (B) Experimental Group (n = 5) that received the hyperglycemic diet for 8 days and was treated from the 9th day of treatment until the 16th day of treatment with an aqueous extract of *Costus spicatus*. The hyperglycemic diet was comprised of feed involved in corn glucose and refined sugar {100 g feed/ 30mL corn syrup (food Yoki glucose basis)/ 30 g sugar (Guarani) Refined}, water substituting 5% dextrose plus refined sugar (500 mL of dextrose/ 100 g of sugar) and daily oral administration of 1 ml of corn syrup diluted in glucose solution (1mL/ 1mL). (A) Control group (n=5) that received the hyperglycemic diet until the 8th day of treatment, like the group treated with the natural extract under study, and from the 9th day treatment started receiving the ad libitum diet (food and water) and oral administration of 0.9% NaCl until the 16th day treatment.

Administration of the extract

The aqueous extract of *Costus spicatus* was administered daily orally (1 mL) with the aid of a gavage needle F1 male mice for 16 days. The animals were divided into two groups (n = 10):

(A) Group previously subjected to a hyperglycaemic diet, and from the ninth day was receiving the diet *ad libitum* five animals with increased blood glucose by oral administration received 0.9% NaCl for a further 16 days. (B) Group previously subjected to a hyperglycemic diet and from the ninth day was receiving diet *ad libitum*, five animals were treated by oral administration of 1 mL of lyophilized aqueous extract of *Costus spicatus* (10 mg/ mL) for 16 days.

Dosage of glucose plasma levels in animals

The assessment of the level of glucose in animals was made from the analysis of the collector ribbon in the meter Accu-Chek Active, where blood samples were used. Each sample collected from a test strip, is equivalent to a drop of blood is obtained from the caudal of the mice. Blood glucose measurements occurred in the days 02/05, 10/05, 18/05 and 26/05, always in the early morning hours, before the animals were fasted for 8 hours.

Results

Organoleptic tests:

Gross extract of *Costus spicatus* showed the following results:

Color: Yellow Amber

Taste: Slightly brackish

pH: 3.7

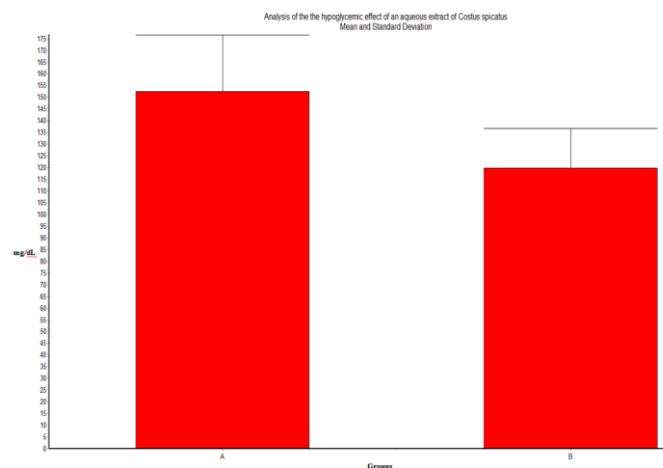


Figure 1: Analysis of the hypoglycemic effect of an aqueous extract of *Costus spicatus*

In the graph of figure 1 can observe the average blood glucose of animals which received only the hyperglycemic diet for 8 days and were treated with physiological saline (0.9% NaCl) for 16 days (A) and the average blood glucose of animals that received the hyperglycemic diet over 8 days and treated with an aqueous extract of *Costus spicatus* for 16 days (B).

From the analysis of the results it can be inferred that there was a statistically significant difference ($p < 0.005$) when compared to the untreated group (A) with the group treated with an aqueous extract of *Costus spicatus* (B).

Statistical analysis

Regarding Analysis of the hypoglycemic effect of an aqueous extract of *Costus Spicatus*, whose graph is shown in Figure 1, data were analyzed based on statistical analysis applying a Paired t-test. In figure 2 one can see the graph relating to the Analysis at the level of linear regression of the hypoglycemic effect of an aqueous extract of *Costus Spicatus*, the results obtained were treated from the statistical analysis applying a Linear Regression test.

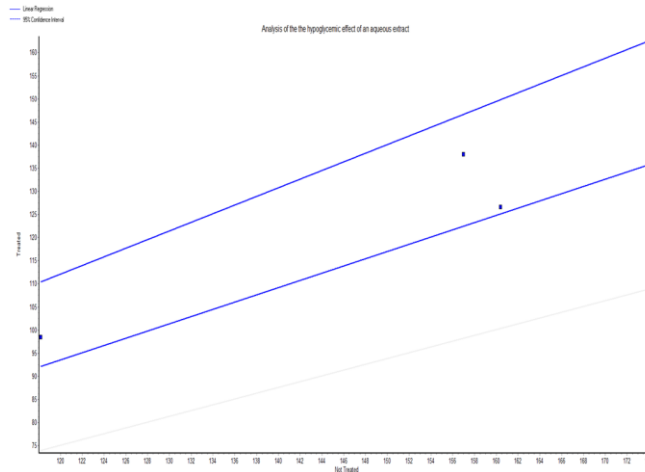


Figure 2: Analysis at the level of linear regression of the hypoglycemic effect of an aqueous extract of *Costus spicatus*

In the graph of figure 2 can observe the average blood glucose of animals Which only received the hyperglycemic diet for 8 days and Were treated with physiological saline (0.9% NaCl) for 16 days (Not Treated group = Y) and the average blood glucose of que animals received the diet hyperglycemic over 8 days and treated with an aqueous extract of *Costus spicatus* for 16 days (treated group = X).

From the analysis of the results it can be inferred que there was a statistically significant difference ($p < 0.005$) When Compared to the untreated group (A = X) with the group treated with an aqueous extract of *Costus spicatus* (B = Y).

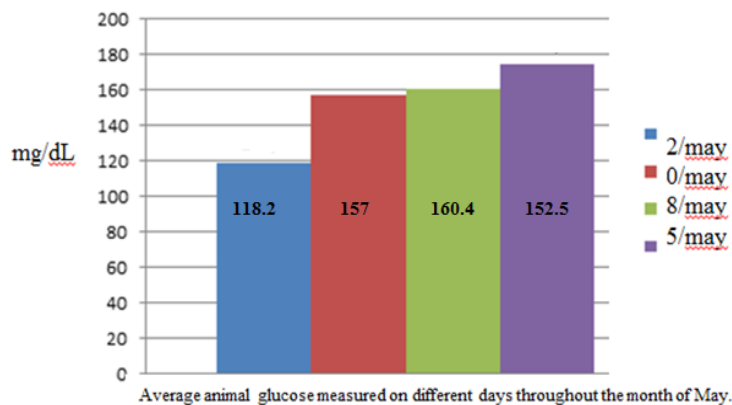


Figure 3: Evaluation of average blood glucose of animals that were treated with hyperglycemic diet

The blood sugar of the animals was assessed on days 02/05, 10/05, 18/05 and 26/05. In the Figure 3 graph can be seen the average blood glucose measurements performed in their days throughout the month of May.

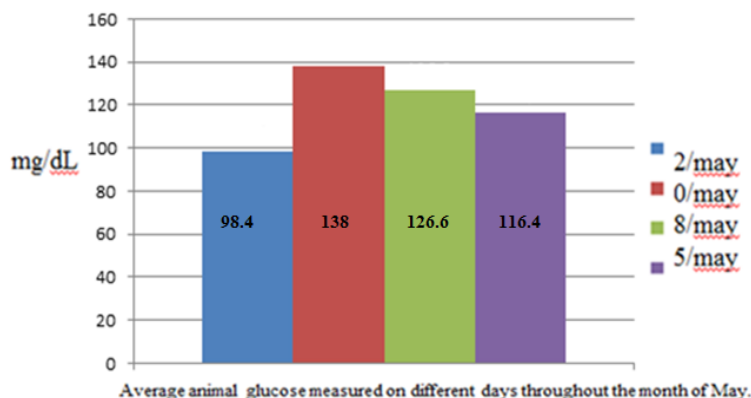


Figure 4: Evaluation of average assessment of blood glucose of animals that were treated with the hyperglycemic diet and who also received an aqueous extract of *Costus spicatus*

The blood sugar of the animals was assessed on days 02/05, 10/05, 18/05 and 26/05. In the Figure 4 graph can be seen the average blood glucose measurements performed in their days throughout the month of May.

Discussion

Plants have been used for the treatment of diabetes from time immemorial. It is increasing the number of people who use herbal remedies as called alternative or complementary medicine for the validation of lesser-known herbal formulations used to treat their illnesses. *Costus speciosus* (Koen ex. Retz.) Sm. (Ginger Crepe, Costaceae family) is an ornamental plant used in traditional medicine for the treatment of inflammation, rheumatism, bronchitis, fever, headache, asthma, flatulence, constipation, helminths, leprosy, skin diseases, hiccups, anemia, as well as burning sensation during urination^[11].

In this study it was observed that the aqueous extract of *Costus spicatus* was able to exert a hypoglycemic effect in animals which were treated with a hyperglycemic diet and subsequently treated with an aqueous extract of *Costus spicatus*.

Nascimento et al. (2016)^[27], proposed that the aqueous extract of *Costus spicatus* has a hypoglycemic effect possibly related to the phytochemical compounds of *Costus spicatus* plant leaves include glycosides, tannins, saponins, terpenoids, phenolics, flavonoids, alkaloids as well as eremanthin which can optimize sugar uptake in the liver. These feats could induce insulin secretion and release from cells, as well as stimulates the tissue's insulin sensitivity leading to an increase of the tissues' glucose uptake, storage, and oxidation.

Interestingly, *Costus pulverulentus* moderate exerts cytotoxic effects on human cancer cells, anti-inflammatory and antinociceptive moderate. The *Costus pulverulentus* induces antinociceptive effects without inducing sedation. It can be speculated that the effects related to the plant extract can be connected to hypoglycaemic action of this induction phytoextract^[28].

It is important to consider the good anti-inflammatory activities exhibited of the isolated compounds from *Costus speciosus* corroborate the usefulness of this plant in the traditional treatment of inflammation and related symptoms^[11]. According to the referred authors, the n-hexane-CHCl₃ soluble fraction afforded a new eudesmane acid, specioic acid (8), along with seven known compounds, 22, 23 dihydrospinasterone (1), dehydrodihydrocostus lactone (mokko lactone) (2), dehydrocostus lactone (3), stigmasterol (4), arbusculin A (5), santamarine (douglanin) (6), and reynosin (7). Compounds 1, 4, and 5-7 were isolated for the first time *C. speciosus*. Compounds 1-4 displayed potent anti-inflammatory activity, while 7 and 8 showed moderate activity. Compounds 1-8 exhibited a concentration-related decrease in the levels of IL-1 β , IL-6, TNF- α , PGE2, lipoxgenase-5, and COX-2. Compounds 5 and 6 did not significantly decrease levels of different cytokines, PGE2, lipoxgenase-5, and COX-2 from PHA treatment at 1 μ M. However, all tested compounds significantly decreased cytokines, PGE2, lipoxgenase5, and COX-2 levels at concentration 100 μ M. It is noteworthy that compounds 1-4 had the highest activity, where it lowered levels of cytokines, PGE2, lipoxgenase-5, and COX-2 to the extent that was no statistical difference from the control group.

Thus, they decreased pro-inflammatory cytokines (IL1 β , IL-6, and TNF- α) with decreased level of the target enzymes (COX-2 and lipoxgenase-5) and subsequent reduction of its inflammatory product (PGE2). These findings could complement those observed by Nascimento et al., (2015)^[27] where it was observed that interestingly, the anti-hemolytic action related to an aqueous extract of *Costus spicatus* would be possibly related to the presence of phenolic molecules in the extract, which would have its most obvious action spectrum in more dilute salt concentrations while saponins molecules exhibit its effect at lower concentrations saline, with its more free hydroxyl groups in this way, these hydroxyl groups may join possible towards oxidative reactions such as the Fenton reaction in the presence of heme plus interact with membrane proteins such as transport proteins band 3 and pump Na⁺/K⁺ATPase, besides interacting with the membrane lipid peroxidation promoting actions that could possibly contribute to achieve osmotic fragility of erythrocyte membrane and consequent hemolysis.

Ezejiolor et al. (2016)^[29] describer that the phytoconstituents of *Costus afer* Ker Gawl leaves include glycosides, tannins, saponins, terpenoid, phenolic compound, flavonoids, and alkaloids. *Costus afer* possessed significant hypoglycemic ($p < 0.05$) effect and reversed the histopathologic damage of pancreases in alloxan-induced diabetic rats comparable to those of glibenclamide. Similarly we observed in our experiments one hypoglycemic action of the aqueous extract of *Costus spicatus* in animals that were treated with a hyperglycemic diet.

We can speculate that, like Ali et al., (2014)^[30] reported a possible anti-hyperglycemic activity exerted by *Costus speciosus*, the *Costus spicatus* extract evaluated in this study has a similar action, since the induction of insulin secretion from cells and stimulates insulin sensitivity of tissues, which leads to an increased glucose uptake, storage and oxidation in tissues.

The increasing prevalence of diabetes mellitus worldwide is an issue of major socio-economic concern. Diabetes mellitus is a complex and a multifarious group of disorders that disturbs the metabolism of carbohydrates, fat and protein. Medicinal plants play an important role in the management of diabetes mellitus especially in developing countries. *Costus speciosus* is widely used in Indian medicine to treat various diseases. Eliza et al. (2009)^[31] related that Eremanthin was isolated from *C. speciosus*. They indicated that eremanthin possessed hypoglycemic and hypolipidemic activities and hence it could be used as a drug for treating diabetes. Additionally, we can speculate that the hypoglycemic effect of an aqueous extract of *Costus spicatus* observed in our experiment could be related to the possible action of eremanthin and/ or with the action set of plant molecules which could express a common functional synergy of phytocomplex.

Plant-derived extracts have been used as folk remedies for Type 2 diabetes mellitus (T2DM) for many centuries, and offer the potential of cheap and readily available alternatives to conventional pharmaceuticals in developing countries. According to Al-Romaiyan et al., (2010)^[32] extracts of *Costus pictus* (CP), a plant belonging to the Costaceae family, are reported to have antidiabetic activity *in vivo*. The exact molecular mode of action(s) of CP is unclear but the antihyperglycemic effect seen in animal studies was associated with dramatic increases in insulin secretion so in their study has been measured the effect of aqueous CP extract on insulin secretion *in vitro* from the MIN6 β -cell line and isolated mouse and human islets. Their data demonstrate that CP has a direct stimulatory effect on insulin secretion at basal but not stimulatory glucose concentrations which was not associated with compromised membrane integrity or decrease β -cell viability. Similar effects were described by Eliza et al., (2009)^[31] relating to the hypoglycemic effect of *Costus speciosus* and by Nascimento et al., (2016)^[27] and Nascimento et al., (2015)^[33] which had described the hypoglycemic effect of *Costus spicatus* as well as its actions protecting the integrity of cell membrane and consequently a possible action which could preserve the physiology of transmembrane transport and cellular homeostasis. Al-Romaiyan et al., (2010)^[32], related that single cell calcium microfluorimetry measurements showed that CP caused elevations in β -cell intracellular Ca(2+) concentrations ([Ca(2+)](i)), an effect which was completely abolished by the removal of extracellular Ca(2+) or blockade of voltage-gated Ca(2+) channels (VGCC). These *in vitro* observations suggest that one mode of action of CP is through stimulating insulin secretion which may be mediated, in part, by the ability of CP to increase [Ca(2+)](i) levels through VGCC. CP extracts may provide an affordable and inexpensive alternative for treating patients with T2DM. Based on our results we can speculate on a complementary basis, that certain molecules with possible antioxidant present in the aqueous extract of *Costus spicatus*, could act at the cellular membrane level, allowing greater insulin secretion in pancreatic level while optimizing greater glucose uptake at the cellular

level, contributing this way to the expression of a related hypoglycemic effect with the aqueous extract of *Costus spicatus* studied.

Conclusion

From the results of this study can be speculated that the aqueous extract studied *Costus spicatus* has a potential hypoglycemic action could be related to the synergic action of molecules with antioxidant profile which can enhance the secretion of insulin by the pancreas and the increase in absorption of tissue glucose level. Based on evidence from the analysis of the results, then, suggest that the effect of decreasing glucose *Costus Spicatus* extract could be associated with the enhancement of insulin release from pancreatic islets and enhancing peripheral glucose utilization.

Acknowledgement

We thank the promotion for research at the Foundation for Research of the State of Rio de Janeiro - FAPERJ.

References

1. Rezende J.R., Rodrigues S.B., Jabor I.A.S., Pamphie J.A., Rocha L.M.S.C., Efeito antimutagênico do látex de *Euphorbiatirucalli* no sistema metionina em *Aspergillus nidulans*, Acta Scientiarum Biological Sciences, 26(4), 481-484, (2004)
2. Silva Junior A.A., Plantas medicinais. Florianópolis: EPAGRI. (CD-ROM) (1998)
3. Lorenzi H., Matos F.J.A., Plantas medicinais no Brasil. Nova Odessa, SP: Instituto Plantarum, 512, (2002)
4. Specht C.D., KRESS W.J., Stevenson D.W., Desalle R.A., Molecular phylogeny of Costaceae (Zingiberales). Molecular Phylogenetics and Evolution, 21(3), 33-345, (2001)
5. Specht C.D., Stevenson W.A., New phylogeny-based generic classification of Costaceae (Zingiberales). Taxon, 55(1), 153-163, (2006)
6. Angiosperm Phylogeny Group – (APG III). An update of the angiosperm phylogeny group classification for the orders and families of flowering plants, Botanical Journal of the Linnean Society, 161, 105-121, (2009)
7. Lorenzi H., Matos F.J.A., Plantas medicinais no Brasil: nativas e exóticas. 2.ed. Nova Odessa, SP: Instituto Plantarum, 544, (2008)
8. Petersen O.G., *Costus spicatus* (Zingiberaceae). Flora Brasiliensis, 3(3), 52, (1990)
9. Borrás, M.R.L., Plantas da Amazônia: medicinais ou mágicas - Plantas comercializadas no mercado Adolpho Lisboa. Manaus: Valer, 322 (2003)
10. Gasparri S., Estudo da atividade antioxidante mutagênica/antimutagênica induzida pelo extrato vegetal da *Costus*, Dissertação (Mestrado – Área de concentração em Diagnóstico Genético e Molecular) - Universidade Luterana do Brasil, Canoas, 78, (2005)
11. Al-attas A.A., El-shaer N.S., Mohamed G.A., Ibrahim S.R., Esmat A., Anti-inflammatory sesquiterpenes from *Costus speciosus* rhizomes, J. Ethnopharmacol. 24, 176, 365-74, (2015)
12. Boorhem R.L., Segredos e virtudes das plantas medicinais, Rio de Janeiro: Reader's Digest Brasil Ltda 416 (1999)
13. Albuquerque J.N., Plantas medicinais de uso popular. Brasília: ABEAS, 100, (1989)

14. Silva L.N., Aspectos anatômicos e etnofarmacológicos de *Bonamia ferruginea* (Choisy) Hallier (Convolvulaceae). 100p. Dissertação (Mestrado – Área de concentração em Botânica) – Departamento de Botânica, Instituto Nacional de Pesquisa da Amazônia, Manaus (2004)
15. Silva B.P., Bernardo R.R., Parente J.P., Flavonol glycosides from *Costus spicatus*. *Phytochemistry*, 53, 87-92, (2000)
16. Haraguchi H., Kuwata Y., Inada K., Shingu K., Miyahara K., Nagao M., Yagi A., Antifungal activity from *Alpinia galanga* and the composition for incorporation of unsaturated fatty acid in cell growth, *Planta Medica*, 62, 308-313, (1996)
17. Salvador M., Henriques J.A.P., Radicais livres e a resposta celular ao estresse oxidativo. 1 ed. Editora da ULBRA, Canoas, 200 (2004)
18. Vieira L.S., Albuquerque J.M., Fitoterapia Tropical - Manual de Plantas Mediciniais. FCAP - Serviço e Documentação e Informação. Belém (1998)
19. Hegde P.K., Rao H.A., Rao P.N., A review on Insulin plant (*Costus igneus* Nak). *Pharmacogn Rev.*, 8(15), 67-72 (2014)
20. Sugiyama K-I., Izawa S., Inoue Y., The Yap1p-dependent induction of glutathione synthesis in heat shock response of *Saccharomyces cerevisiae*, *Journal of Biological Chemistry*, 275, 15535-15540 (2000)
21. Azevedo L.F.P., Faria T.S.A., Pessanha F.F., Araujo M.F., Iemos G.C.S., Phytochemical screening and antioxidant activity of *Costus spicatus* (Jacq.) Sw. *Rev. bras. plantas med.*, 16(2), (2014)
22. The Expert Committee on the Diagnosis and Classification of Diabetes Mellitus (ECD/CDM). Report of the Expert Committee on the diagnosis and classification of diabetes mellitus. *Diabetes Care*, 20, 1183-97, (1997)
23. UK Prospective Diabetes Study (UKPDS) Group. Intensive blood-glucose control with sulphonylureas or insulin compared with conventional treatment and risk of complications in patients with type 2 diabetes (UKPDS 33), *Lancet*, 352, 837-53, (1998)
24. Medagama A.B., Senadhira D., Use of household ingredients as complementary medicines for perceived hypoglycemic benefit among Sri Lankan diabetic patients, a cross-sectional survey, *J. Intercult Ethnopharmacol.*, 4(2), 138-42, (2015)
25. Dourado R.S., Ladeira A.M., Identificação de flavonóides em *Hypericum cordatum* (Vell.) N. Robson (Clusiaceae), *Rev. bras. Bot.*, 31(4), 611-620 (2008)
26. Farmacopéia Brasileira 4 ed., Ed., Atheneu, São Paulo (1988)
27. Nascimento C.C.H.C., Azevedo L.A.C., Camacho A.C.L.F., Oliveira J.F.F., Gomes M.L., Nascimento S.F., Vasconcelos S.D.D.DE, Nogueira R.I., Barreto A.S., Diré G.F., Analysis of hypoglycemic effect of na aqueous extract of *Costus spicatus* on F1 mice subjected to hyperglycemic diet, *Int. J. Adv. Res. Biol. Sci.*, 3(2), 99-107 (2016)
28. Alonso-Castro A.J., Zapata-Morales J.R., González-Chávez M.M., Carranzaálvarez C., Hernández-Benavides D.M., Hernández- Morales A., Pharmacological effects and toxicity of *Costus pulverulentus* C. Presl (Costaceae), *J. Ethnopharmacol.*, Jan 14. pii: S03788741(16)30011-3. doi: 10.1016/j.jep.2016.01.011.(2016)
29. Ezejiofor A.N., Orish C.N., Orisakwe O.E., Morphological changes in the pancreas and glucose reduction of the aqueous extract of *Costus afer* leaf on alloxan-induced diabetic rats, *J. Basic Clin. Physiol. Pharmacol.*, 26(6), 595-601, (2015)

30. Ali H.A., Almaghrabi O.A., Afifi M.E., Molecular mechanisms of anti-hyperglycemic effects of *Costus speciosus* extract in streptozotocin-induced diabetic rats, *Saudi Med. J.*, 35(12),1501-6 **(2014)**
31. Eliza J., Daisy P., Ignacimuthu S., Duraipandiyar V., Antidiabetic and antilipidemic effect of eremanthin from *Costus speciosus* (Koen.)Sm., in STZ-induced diabetic rats. *Chem. Biol. Interact.*, 10, 182(1), 67-72 **(2009)**
32. Al-romaiyan A., Jayasri M.A., Mathew T.L., Huang G.C., Amiel S., Jones P.M., Persaud S.J., *Costus pictus* extracts stimulate insulin secretion from mouse and human islets of Langerhans in vitro, *Cell Physiol Biochem.*, 26(6), 1051-8, **(2011)**
33. Nascimento C.C.H.C., Azevedo L.A.C., Peixoto A.G., Vieira T.O., Camacho A.C.L.F., Oliveira J.F.F., Gomes M.L., Nascimento S.F., Pinto P.R., Barreto A.S., Diré G.F., Spectrophotometric and haemolytic analysis of a extract of *Costus spicatus*, *European Journal of Biology and Medical Science Research (E.J.B.M.S.R.)* 3(1), 29-58 **(2015)**